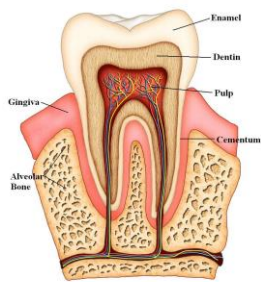


Cracked Tooth

When the outer hard tissues of the tooth are cracked, chewing can cause movement of the pieces and the pulp can become irritated. When biting



pressure is released, the crack can close quickly, resulting in a momentary, sharp pain. Eventually, the pulp will become damaged to the point that it can no longer heal itself. The tooth will hurt when chewing and also become sensitive to temperature extremes. In time, a cracked tooth may

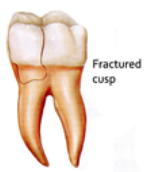begin to hurt all by itself. Extensive cracks can lead to infection of the pulp tissue, which can spread to the bone and gum tissue surrounding the tooth. It is sometimes difficult to diagnose a cracked tooth since it is not visible on an x-ray. Efforts are made to treat the tooth conservatively but occasionally the tooth will need subsequent treatment if previous treatment has not helped.

Craze Lines

Craze lines are tiny cracks that affect only the outer enamel. These cracks are extremely common in adult teeth. Craze lines are very shallow, cause no pain, and are of no concern beyond appearance.

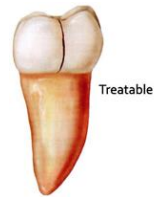
Fractured Cusp

When a cusp (the pointed part of the chewing surface) becomes weakened, a fracture sometimes results. The weakened cusp may break off by itself or may have to be removed by the dentist. When this happens, the pain will usually be relieved. A fractured cusp rarely damages the pulp, so root canal treatment is seldom needed. The tooth will usually be restored by your dentist with a full crown.

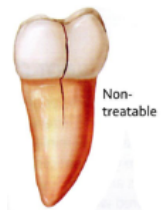

Cracked Tooth

This crack extends from the chewing surface of the tooth vertically towards the root. A cracked tooth is not completely separated into two distinct segments. Because of the position of the crack, damage to the pulp is common. Root canal treatment is frequently needed to treat the injured pulp. Your dentist will then restore your tooth with a full crown to bind and protect the cracked tooth. At times, the crack may extend below the gum line, requiring extraction.

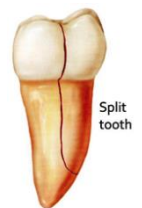

Early diagnosis is important. Even with high magnification and special lighting, it is sometimes difficult to determine the extent of a crack. A cracked tooth that is not treated will eventually result in the loss of the tooth. Early diagnosis and treatment are essential in saving these teeth.



Split Tooth

A split tooth is often the result of the long-term progression of a cracked tooth. The split tooth is identified by a crack with distinct segments that can be separated. If possible, the cracked part of the tooth is removed, and the tooth is then restored with a filling or crown. However, if the crack extends below the bone, the tooth will need to be extracted since these types of cracks cannot be repaired.



Vertical Root Fracture

Vertical root fractures are cracks that begin in the root of the tooth and extend toward the chewing surface. They often show minimal signs and symptoms and may therefore go unnoticed for some time. Vertical root fractures are often discovered when the surrounding bone and gum become infected. Treatment usually involves extraction of the tooth.

